



# Maximizing patient benefit through a reversed pathway from specialist to generalist: the case of chronic pain

Ioannis Karageorgiou<sup>1</sup>, Stamatios Kokkinakis<sup>1</sup>, Neofytos Maliotis<sup>1</sup>, Christos Lionis<sup>2</sup>, Emmanouil K Symvoulakis<sup>2</sup>

1) School of Medicine, University of Crete, Heraklion, Greece

2) Clinic of Social and Family Medicine, School of Medicine, University of Crete, Heraklion, Greece

## Abstract

Polymyalgia Rheumatica (PMR) is a syndrome characterized by chronic pain and/or stiffness in the neck, shoulders or upper arms and hips. It affects adult patients usually over 50 years old and is treated with low-dose oral corticosteroids. In this case, a 68-year-old female with a history of PMR, diagnosed by a specialist sporadically seen in the past, presented to a primary care physician due to herpes zoster (HZ) infection. Thorough history taking, along with a careful review of previous laboratory results, raised serious doubts concerning her diagnosis (PMR). Because the patient described diffuse pain throughout her body, sleep disturbances and a depressed emotional state, fibromyalgia was suspected instead and appropriate treatment was given. The patient remained free of symptoms and corticosteroids for almost a year. Information from this case may help to point out that PMR is a disorder that can be easily confused with other chronic pain conditions with similar manifestations, especially when the initial diagnosis is sped up in terms of consultation depth and care continuity. Under certain circumstances, primary care can lead to improved clinical outcomes.

**Keywords:** primary health care, polymyalgia rheumatica, fibromyalgia, herpes Zoster

## Introduction

Polymyalgia rheumatica (PMR) is an inflammatory rheumatic disorder characterized by aching and morning stiffness for more than 45 minutes around the neck, shoulders, and hip girdle [1]. The annual incidence of PMR in a predominantly Caucasian population of adults 50 years old or older is estimated between 58-96 cases in 100,000 [1]. Incidence increases with age until the age of 80 years in both sexes [1]. More than two-thirds of patients are women [1,2]. PMR lists second after rheumatoid arthritis as an inflammatory systemic rheumatic disease in adults [3]. PMR is much less frequent in African American, Asian, and Hispanic population groups. The treatment of choice for PMR is oral prednisolone [4-6]. In most cases, the sufficient effective dose of prednisolone is ranging from 12.5 to 25 mg per day [4-

7]. In the majority of cases, the patient's dose is individualized and dose reduction may frequently occur during the following months, based on clinical benefit obtained.

Our aim in this case is to emphasize the clinical value of follow-up continuity within primary care settings, by describing a 'care episode' of a female patient who visited a general practitioner (GP) with a unilateral facial rash while she was on treatment for PMR, with a prescription of daily corticosteroids for more than nine months.

## Case Report

A 68-year-old woman visited her GP after developing a unilateral left side facial rash the previous night. Patient history revealed dyslipidemia, hypertension, and PMR for which she was being treated with oral corticosteroids (5 mg daily at the moment of visit and

DOI: 10.15386/mpr-1873

Manuscript received: 27.08.2020

Received in revised form: 31.12.2020

Accepted: 01.02.2021

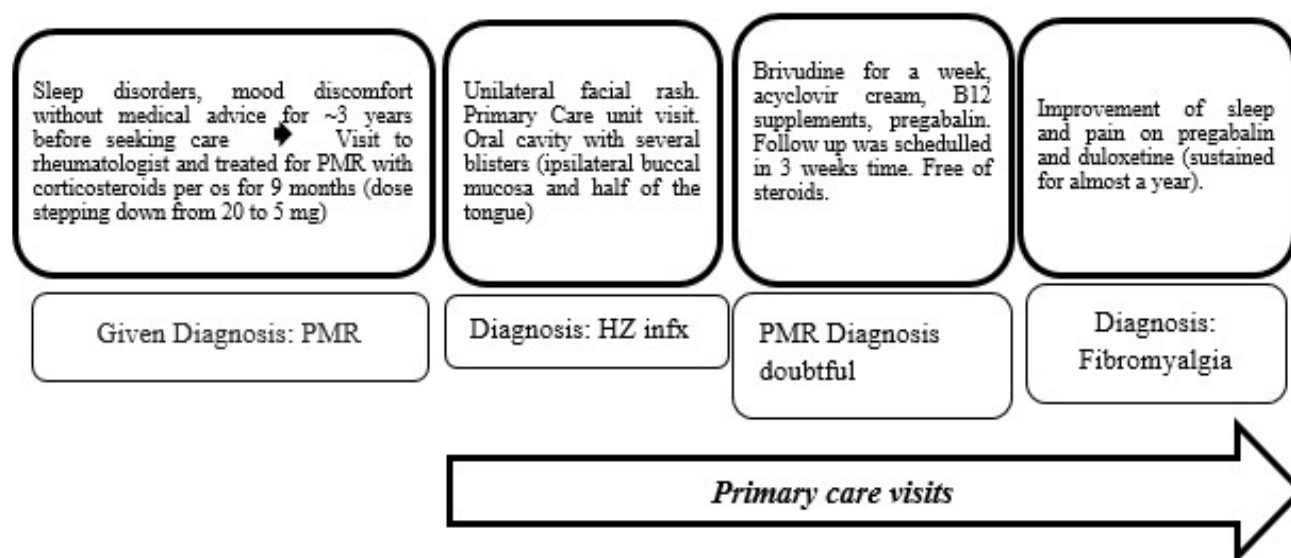
Address for correspondence:  
ionkarag@gmail.com

This work is licensed under a Creative Commons Attribution-NonCommercial-NoDerivatives 4.0 International License

after months of gradual dose reduction). The patient did not smoke or drink alcohol. Family history did not reveal any rheumatologic diseases in first-degree relatives. Her daily medications, apart from the aforementioned corticosteroids, were Ezetimibe/Simvastatin 10/20 mg s:1x1 orally and Telmisartan/ Hydrochlorothiazide 80/12.5 mg s:1x1 orally. Height was 157 cm and BMI 24.7 kg/m<sup>2</sup>. A previous varicella zoster virus (VZV) infection was also confirmed from patient history. Clinical examination of the face showed multiple confluent erythematous blisters on the skin of the left cheek. External auditory meatus and eyes were normal at the time of inspection. On oral cavity examination, several blisters were noted on the ipsilateral left buccal mucosa and ipsilateral left half of the tongue. Signs of ophthalmic nerve branch involvement were not present. Considering both chronic corticosteroid use and typical clinical presentation, a clinical diagnosis of trigeminal herpes zoster (HZ) was made [8]. The patient was started on brivudine 125 mg daily for a week, pregabalin three times daily for at least a month (25 mg: 2-1-2), acyclovir cream four times daily until skin lesion restoration and vitamin B12 at a supplemental dose for a month. Steroids were stopped properly and a follow-up examination was scheduled. Clinical examination also revealed several bilateral tender points: neck, chest, shoulder girdle, upper arms, upper back, lower back, hips, and upper legs. On follow-up examination after three weeks, no skin lesion was present and the patient mentioned a significant improvement of her chronic pain, even though she had not been receiving corticosteroids during this time interval.

Previous laboratory results, at the time of the PMR diagnosis from a specialist rheumatologist, seen sporadically (more than nine months before the HZ infection), were as follows: Erythrocyte sedimentation rate (ESR) = 32mm/h and Hematocrit (Hct) = 39%, lab findings not typical for PMR (typically an ESR > 50 mm/h and normocytic anemia is expected). History of giant cell arteritis symptoms, such as headaches or blurred vision, was negative. The current lab values (after three weeks from infection) were very similar. C- reactive protein, C3, C4, ANCA-P, ANCA-C, ANA were normal. The patient also described sleep disorders during the last three years. The patient described significant pain despite daily corticosteroid treatment (prednisolone 20 mg). Given the non-supportive lab findings, the marked improvement of the patient's chronic pain all over the mentioned points after pregabalin and the lack of other systemic symptoms (e.g. fever, weight loss, night sweats) which would point to an inflammatory disorder, a diagnosis of fibromyalgia (FM) was suspected and the patient was started on duloxetine (60 mg daily).

On further follow-up visit after a month, she described an even greater diminution of pain, improved mood, and a significantly better sleep quality due to less pain (self-rated sleep satisfaction before and after was 3 and 8 respectively, on a scale of 0 to 10). In addition, it is important to note that during this month the patient did not have physical therapy or cognitive behavioral therapy sessions. The key points of this case are represented in the following figure (Illustration 1).



**Illustration 1.** Graphic representation of patient's care episode, (PMR: Polymyalgia Rheumatica, HZ: Herpes Zoster, infx: infection).

### Discussion

PMR is a chronic inflammatory disorder that primarily affects adults older than 50 years. It is characterized by morning stiffness and pain around the shoulder and hip girdle [1]. Diagnosis is usually made from weeks to months after the onset of pain [9]. In contrast, FM patients may remain undiagnosed for years [10]. PMR presents with reduced range of motion in the affected joints and patients may also complain of chronic and systemic symptoms [9]. ESR and CRP are usually elevated, and anemia is also present in the majority of patients [9]. Ultrasound examination may suggest bursitis or synovitis of the affected joints [9]. Management typically includes the use of corticosteroids, which alleviate the symptoms for most patients, or steroid-sparing agents such as methotrexate for patients with multiple comorbidities that require long-term treatment [4].

FM is a disorder characterized by centralized diffuse pain, primarily affecting young females [11]. Patients report intermittent pain ‘all over’ the body with multiple tender points, and typically rate their pain as severe. Allodynia and hyperalgesia are often present [10]. Typical comorbidities include depression, non-restorative sleep, and cognitive defects. The minimal duration of pain, along with fatigue or sleep disorders required for a diagnosis of FM, is three months [12]. Patients present with fatigue, pain following exercise, and generalized anxiety. Pain is usually chronic and despite consultations with specialists, many patients cannot find an adequate solution for their problem for years [11]. Diagnosis is mainly clinical and a careful history accompanied by a thorough physical examination can be sufficient. However, clinical diagnostic criteria are used in some cases. In our case the diagnosis was considered straightforward, therefore diagnostic criteria were not applied at the time of patient interview. Retrospective application of the New Fibromyalgia Diagnostic Criteria score [13], based on the available information from the patient’s file, confirmed the diagnosis [Widespread pain index=12, Symptom Severity Score (SS) of 5. Part 2a SS questionnaire indicated that both the cognitive symptoms and waking status were mild. However, the symptoms of fatigue were causing considerable distress to the patient. Accordingly, the score for the Part 2b SS questionnaire was 1, as the patient reported only 4 symptoms] [13]. Lab testing includes inflammatory markers, and Thyroid-Stimulating Hormone (TSH) measurement [11]. Management should typically include cognitive behavioral therapy for generalized anxiety or depression, by providing motivation for aerobic exercise and removing possible stressful factors [10,14]. Pain management typically involves the use of antidepressants, such as amitriptyline or duloxetine and gabapentinoids such as pregabalin or gabapentin [11]. These agents have been used for the treatment of neuropathic pain. However, many patients do not respond to those options, resulting in polypharmacy and further comorbidities [11].

Furthermore, pain in FM can be managed effectively with the help of aerobic and muscle strengthening exercises. Through therapeutic exercises, the global well-being of these patients can be also improved [15].

Blurred diagnostic picture between the two entities can lead to a false diagnosis, and patients can end up suffering from the adverse effects of chronic corticosteroid use. In previous case reports, FM misdiagnosed as PMR resulted in steroid-induced complications, such as hypertension, insulin resistance, and excessive weight gain [16]. A typical confusing factor is obesity, which typically presents with elevated inflammatory markers, pointing towards an inflammatory disorder [16]. Another important point is that patients under the age of 50 are usually not affected by PMR [17]. Complex cases in which those two entities overlap have also been reported [9,17-19].

In our case, a female patient presented to a primary care physician due to a trigeminal Herpes Zoster infection. The reason for the medical visit was the abrupt rash presentation. Thorough history taking, along with a careful evaluation of previous laboratory results, raised serious doubts concerning the diagnosis of PMR made by a specialist sporadically seen in the past. Our patient failed to respond to oral prednisolone, her pain was diffuse (she reported pain ‘all over’ her body) and reported non-restorative sleep for years. Inflammatory markers were atypical for PMR. Pregabalin, primarily prescribed for the HZ infection-related pain, led to partial but consistent relief of the patient’s symptoms, providing another clue for diagnostic revision. Maximum clinical benefit was obtained after duloxetine initiation. The patient remained free from pain symptoms, sleep problems, and corticosteroids for almost a year.

### Conclusion

Information from this case report may help to point out that PMR is a disease that can be easily confused with other chronic pain disorders with similar manifestations, especially when initial diagnosis is sped up in terms of consultation depth and fragmented care. It is therefore very important to keep in mind the clinical and laboratory characteristics of PMR to differentially diagnose it from other similar entities, by appraising all the available case information. An opportunistic reason for consultation, as an infectious disease with acute onset, can lead to clinical review and help improve diagnostic accuracy. In this specific case, the relatively low ESR value (which remained unchanged even after steroid discontinuation) and normal whole blood analysis, pointed out that PMR was less likely to occur, while FM, per definition a neurosensory disorder with no abnormal lab findings, appeared more realistic as a potential diagnosis. In conclusion, a contrary scenario may occur and FM can sometimes be misdiagnosed as PMR, especially in younger patients. Many researchers throughout the years have pointed out the importance of primary health

care and the benefit of continuity [20] at improving patient outcomes. The doctor's diagnostic 'acuity' in this case was enhanced due to a multistep consultation process and meaningful contact with the patient. This case stresses out the role of general practitioners in ensuring and maintaining patient wellbeing.

## References

1. Raheel S, Shbeeb I, Crowson CS, Matteson EL. Epidemiology of Polymyalgia Rheumatica 2000-2014 and Examination of Incidence and Survival Trends Over 45 Years: A Population-Based Study. *Arthritis Care Res (Hoboken)*. 2017;69:1282-1285.
2. Partington RJ, Muller S, Helliwell T, Mallen CD, Abdul Sultan A. Incidence, prevalence and treatment burden of polymyalgia rheumatica in the UK over two decades: a population-based study. *Ann Rheum Dis*. 2018;77:1750-1756.
3. Crowson CS, Matteson EL, Myasoedova E, Michet CJ, Ernste FC, Warrington KJ, et al. The lifetime risk of adult-onset rheumatoid arthritis and other inflammatory autoimmune rheumatic diseases. *Arthritis Rheum*. 2011;63:633-639.
4. Matteson EL, Buttgereit F, Dejaco C, Dasgupta B. Glucocorticoids for Management of Polymyalgia Rheumatica and Giant Cell Arteritis. *Rheum Dis Clin North Am*. 2016;42:75-90, viii.
5. Gonzalez-Gay MA, Agudo M, Martinez-Dubois C, Pompei O, Blanco R. Medical management of polymyalgia rheumatica. *Expert Opin Pharmacother*. 2010;11:1077-1087.
6. González-Gay MA, Castañeda S. Managing of giant cell arteritis and polymyalgia rheumatica. *Expert Opinion on Orphan Drugs* 2016;4:1133-1144.
7. Dejaco C, Singh YP, Perel P, Hutchings A, Camellino D, Mackie S, et al. 2015 recommendations for the management of polymyalgia rheumatica: a European League Against Rheumatism/American College of Rheumatology collaborative initiative. *Arthritis Rheumatol*. 2015;67:2569-2580.
8. Lionis CD, Vardavas CI, Symvoulakis EK, Papadakaki MG, Anastasiou FS, Antonopoulou MD, et al. Measuring the burden of herpes zoster and post herpetic neuralgia within primary care in rural Crete, Greece. *BMC Fam Pract*. 2011;12:136.
9. Matteson EL, Dejaco C. Polymyalgia Rheumatica. *Ann Intern Med*. 2017;166:ITC65- ITC80.
10. Sumpton JE, Moulin DE. Fibromyalgia. *Handb Clin Neurol*. 2014;119:513-527.
11. Gota CE. What you can do for your fibromyalgia patient. *Cleve Clin J Med*. 2018;85:367-376.
12. Arnold LM, Bennett RM, Crofford LJ, Dean LE, Clauw DJ, Goldenberg DL, et al. AAPT Diagnostic Criteria for Fibromyalgia. *J Pain*. 2019;20:611-628.
13. Wolfe F, Clauw DJ, Fitzcharles MA, Goldenberg DL, Katz RS, Mease P, et al. The American College of Rheumatology preliminary diagnostic criteria for fibromyalgia and measurement of symptom severity. *Arthritis Care Res (Hoboken)*. 2010; 62:600-610.
14. Bernardy K, Klose P, Busch AJ, Choy EH, Häuser W. Cognitive behavioural therapies for fibromyalgia. *Cochrane Database Syst Rev*. 2013;2013:CD009796.
15. Sosa-Reina MD, Nunez-Nagy S, Gallego-Izquierdo T, Pecos-Martín D, Monserrat J, Álvarez-Mon M. Effectiveness of Therapeutic Exercise in Fibromyalgia Syndrome: A Systematic Review and Meta-Analysis of Randomized Clinical Trials. *Biomed Res Int*. 2017;2017:2356346.
16. Cheema R, Chang-Miller A, Aslam F. Myalgia with Elevated Inflammatory Markers in an Obese Young Female: Fibromyalgia or Polymyalgia Rheumatica? *Am J Case Rep*. 2019;20:659-663.
17. Park J, Sung DH. Early onset polymyalgia rheumatica: two rare cases under age of 50. *Skeletal Radiol*. 2017;46:837-840.
18. Yokota Y, Namiki H. Pitfalls in diagnosing geriatric general pain: coexistence of polymyalgia rheumatism and fibromyalgia. *BMJ Case Rep*. 2019;12:e230078.
19. Haliloglu S, Carlioglu A, Akdeniz D, Karaaslan Y, Kosar A. Fibromyalgia in patients with other rheumatic diseases: prevalence and relationship with disease activity. *Rheumatol Int*. 2014;34:1275-1280.
20. Maarsingh OR, Henry Y, van de Ven PM, Deeg DJ. Continuity of care in primary care and association with survival in older people: a 17-year prospective cohort study. *Br J Gen Pract*. 2016;66:e531-e539.